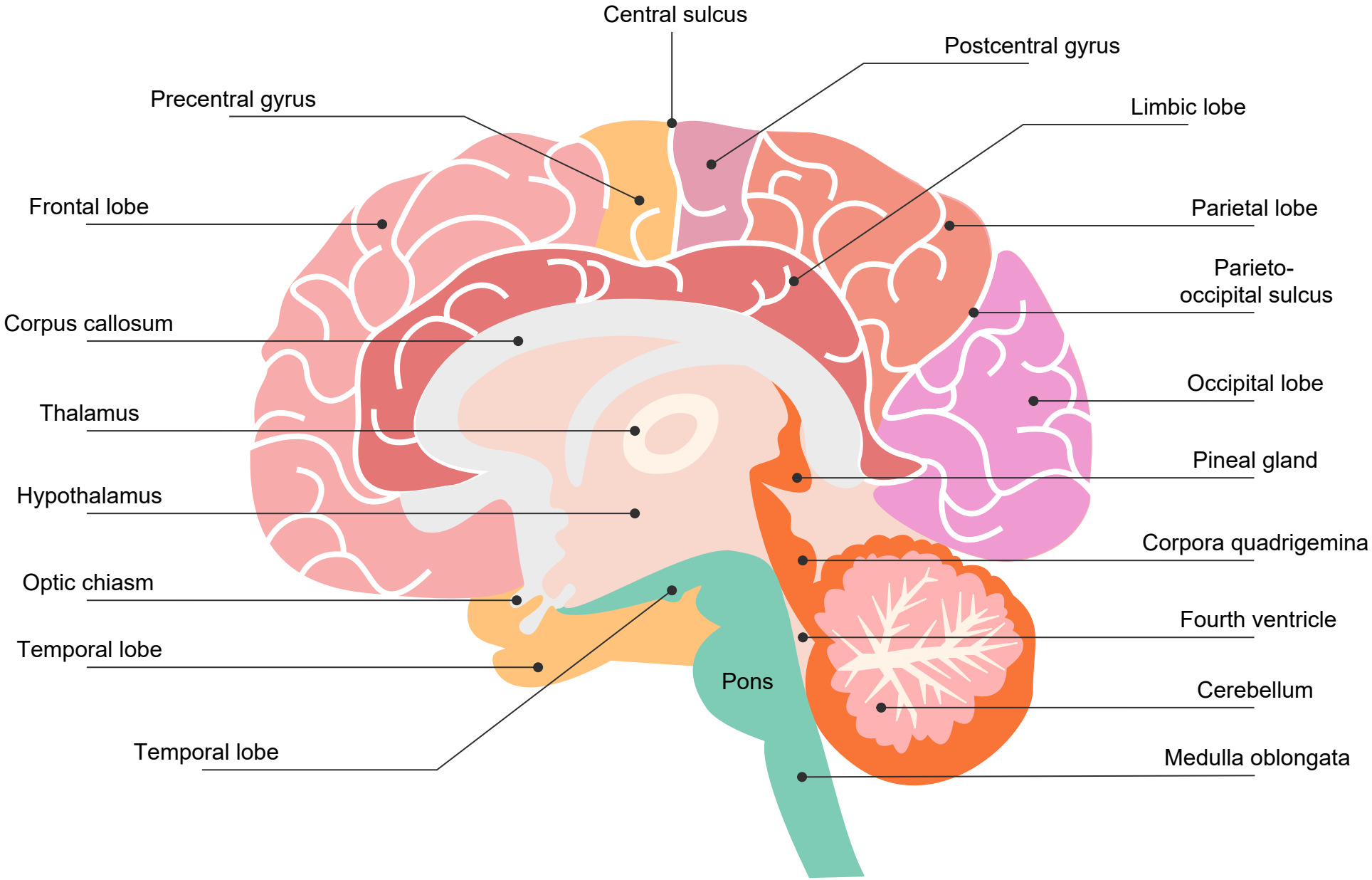
Central sulcus
Postcentral gyrus
Precentral gyrus
Limbic lobe
Frontal lobe
Parietal lobe
Parieto-
occipital sulcus
Corpus callosum
Occipital lobe
Thalamus
Pineal gland
Hypothalamus
Corpora quadrigemina
Optic chiasm
Fourth ventricle
Temporal lobe
Pons
Cerebellum
Temporal lobe
Medulla oblongata